

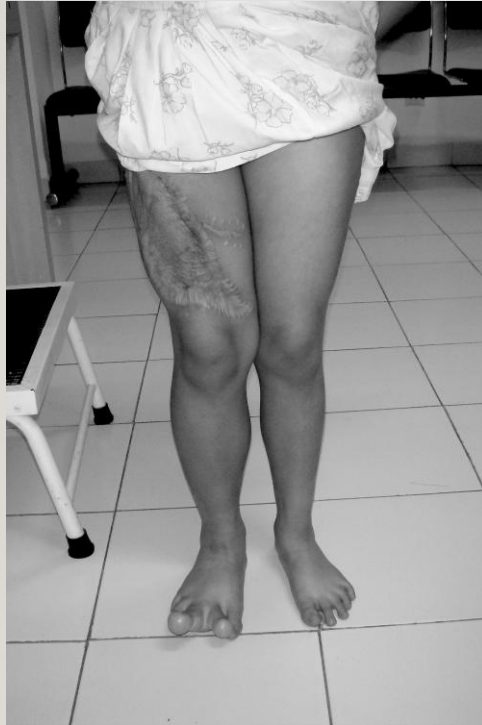MACRODACTYLY (GIGANTISM)

DR RAMANI NARASIMHAN

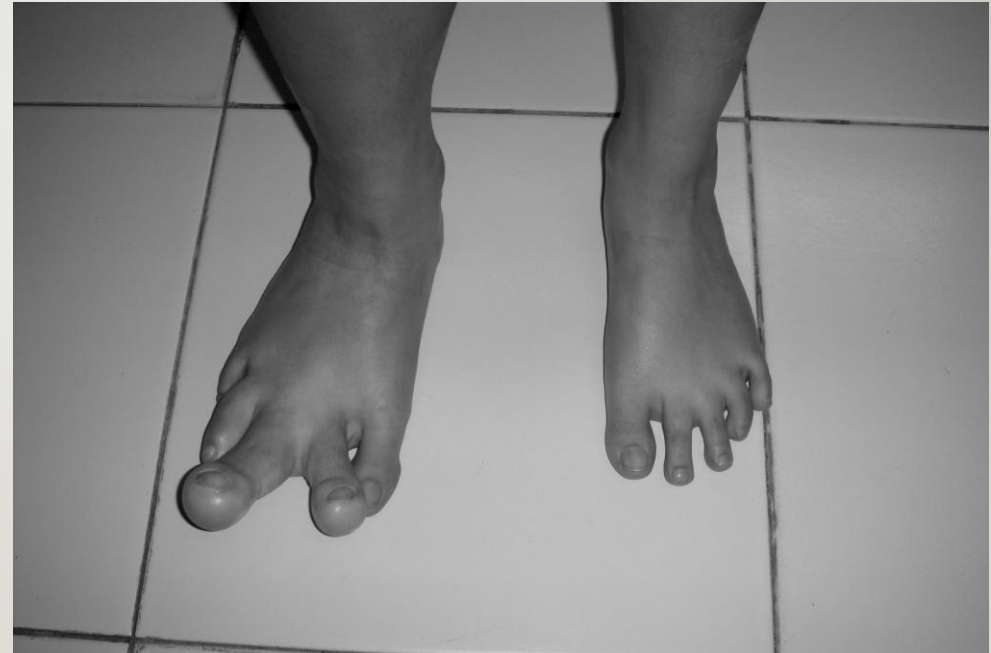SENIOR CONSULTANT PEDIATRIC ORTHOPAEDIC SURGEON

INDRAPRASTHA APOLLO HOSPITALS, NEW DELHI

10 YEAR OLD GIRL RIGHT LOWER LIMB INVOLVEMENT RIGHT FOOT IN PARTICULAR

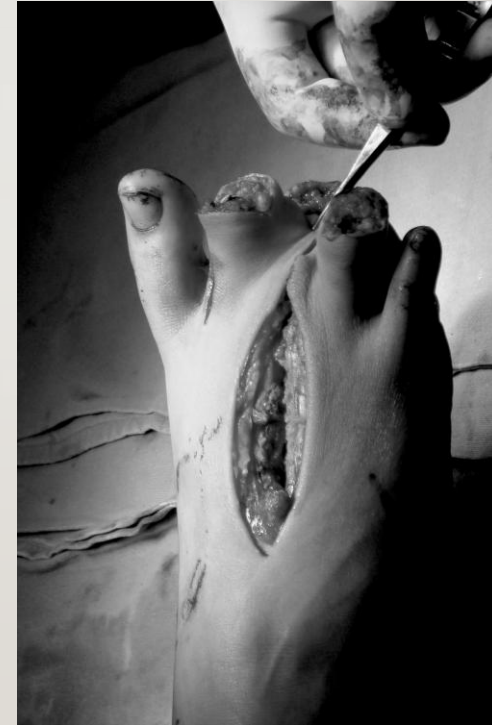
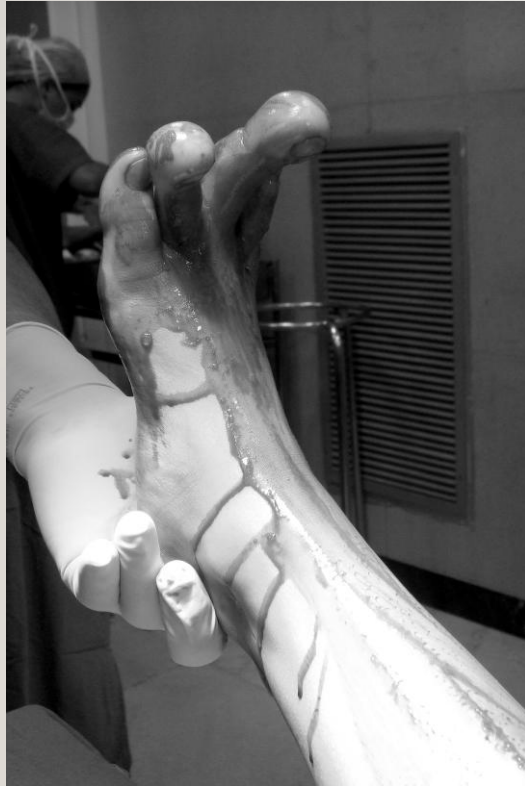

Old burn over thigh
treated elsewhere



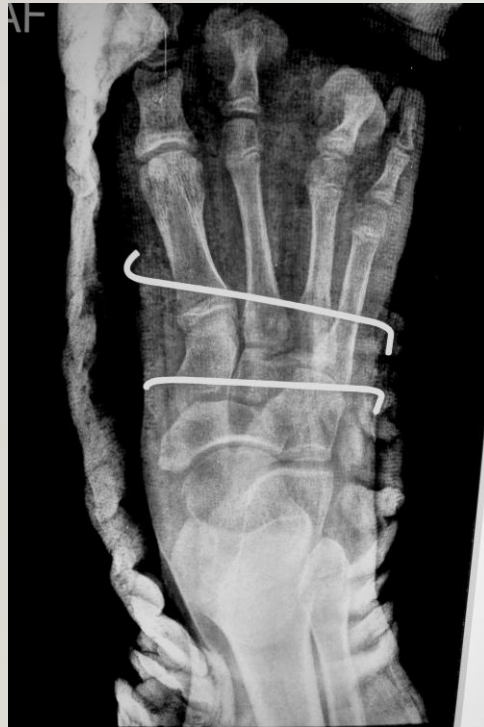2nd & 3rd toes mainly involved
Splaying of foot

PER OPERATIVE

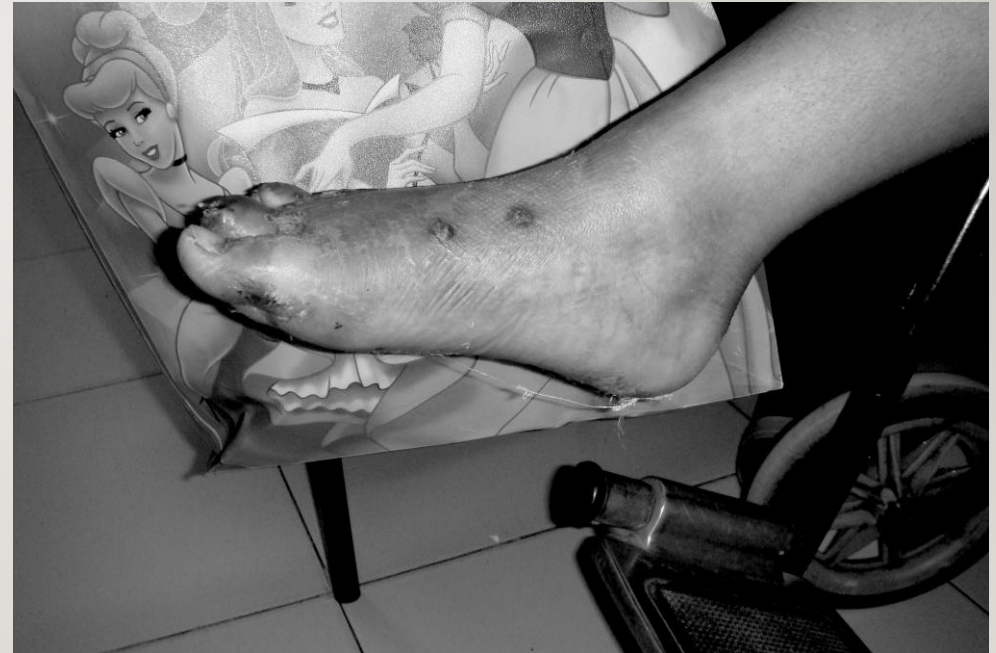

Removal of 3rd ray

POST OP

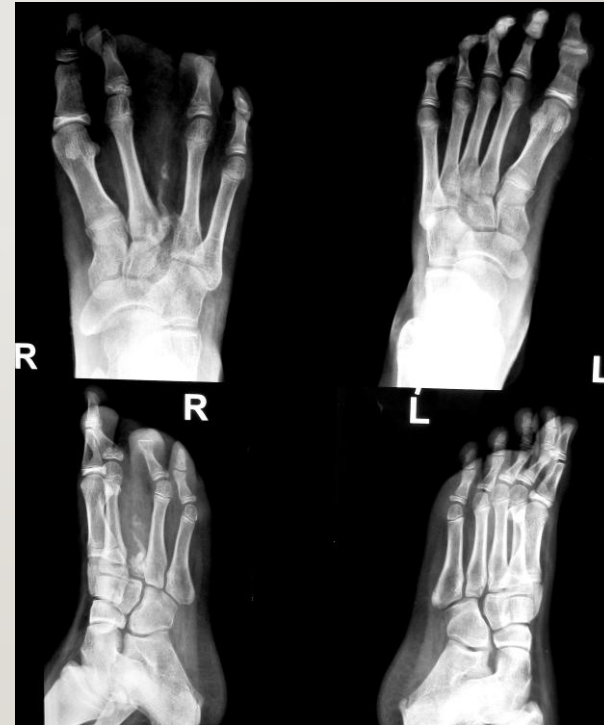
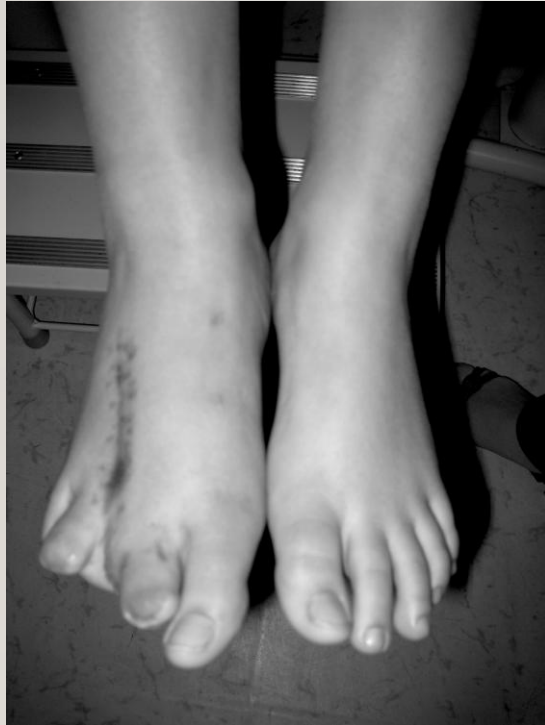

Immediate post-op X-ray



1 month post-op

2 YEARS POST-OP



Wears all footwear comfortably, satisfied