



Adolescent Idiopathic Scoliosis

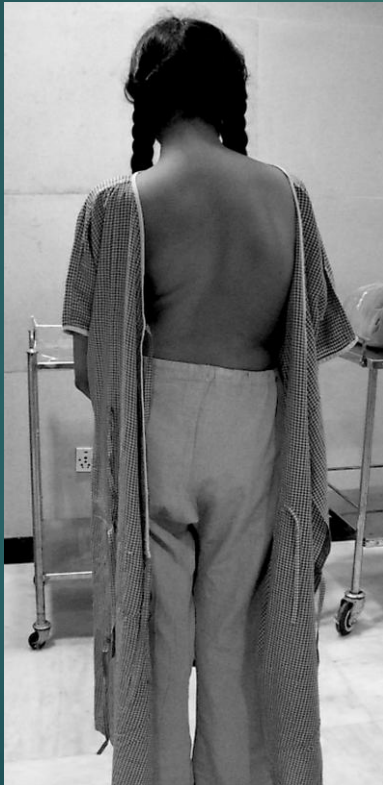DR RAMANI NARASIMHAN

SENIOR CONSULTANT PEDIATRIC ORTHOPAEDIC SURGEON

INDRAPRASTHA APOLLO HOSPITALS, NEW DELHI

16 yr old girl with AIS

Clinical snap

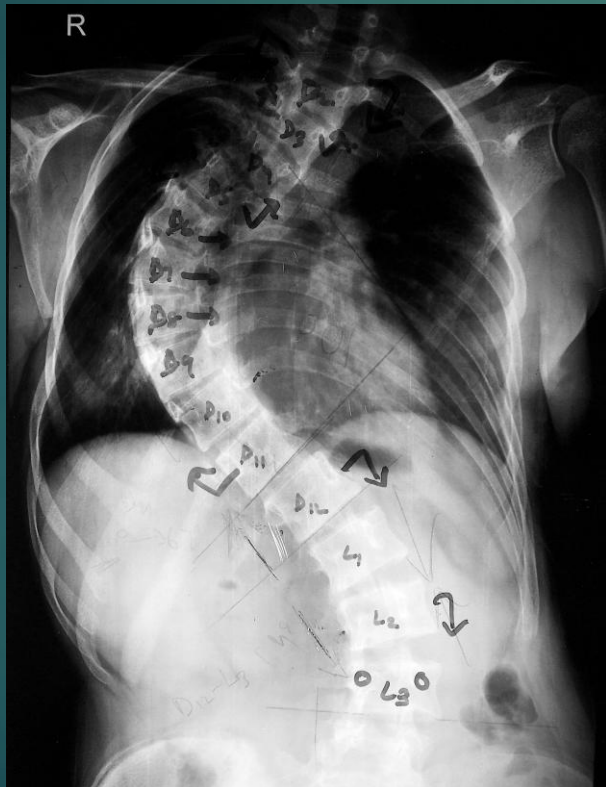


Adam's forward bending test

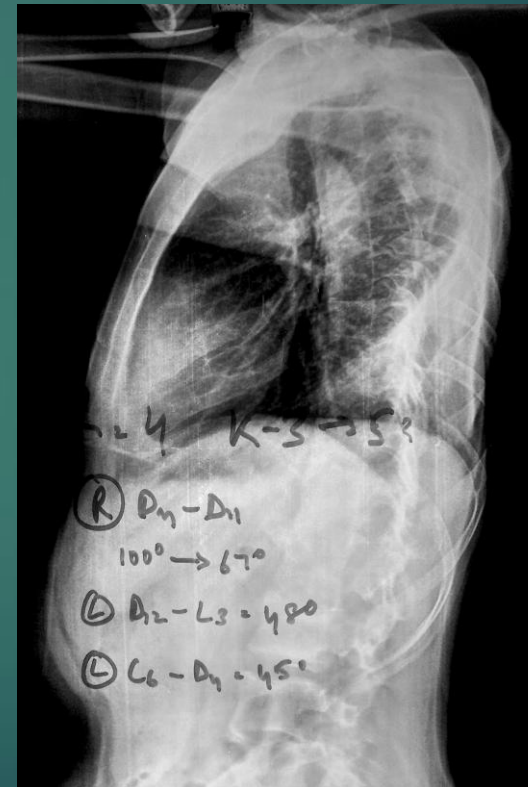


Pre op

Pre-op AP



Pre-op Lat



Planning

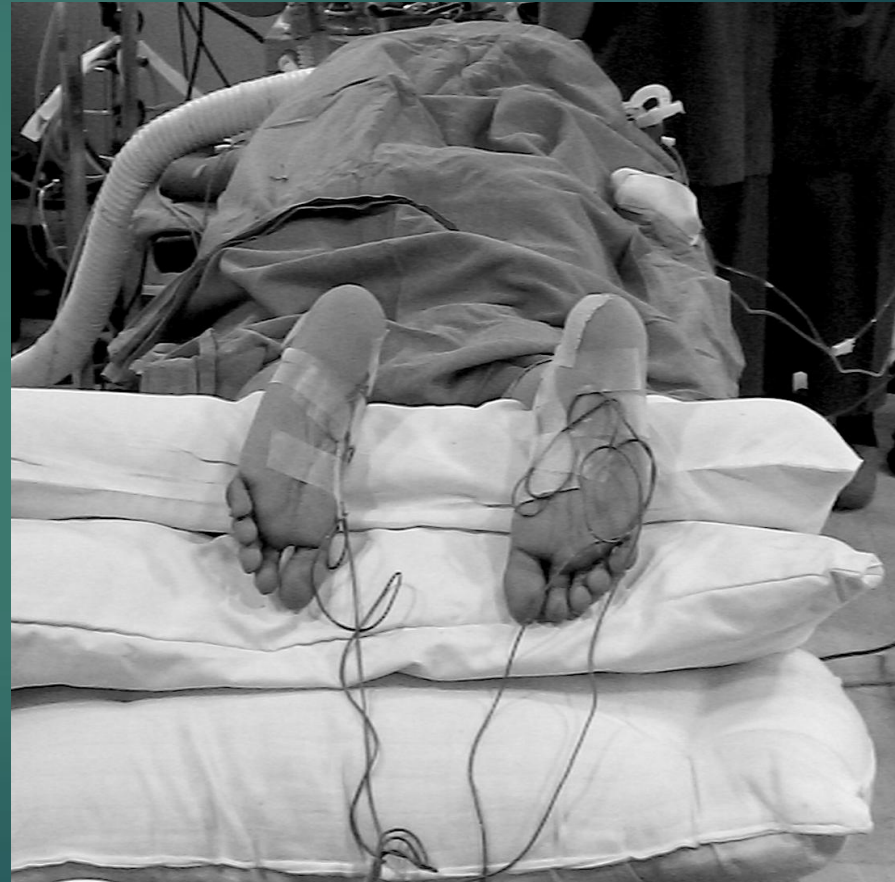- ▶ **Surgery with the aim of:**

- Arresting the curve
 - Balancing the curve
 - Correction

- in order of decreasing priority

- ▶ Thoracoscopic anterior release f/b usage of segmental instrumentation posteriorly & autograft for fusion

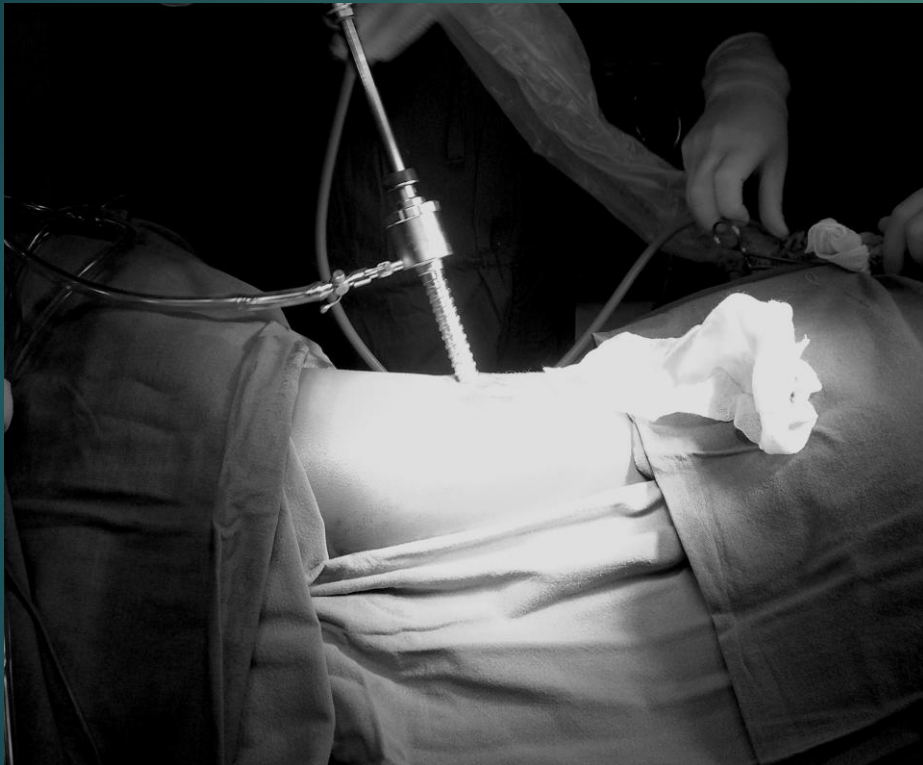- ▶ Usage of per-op spinal cord monitoring



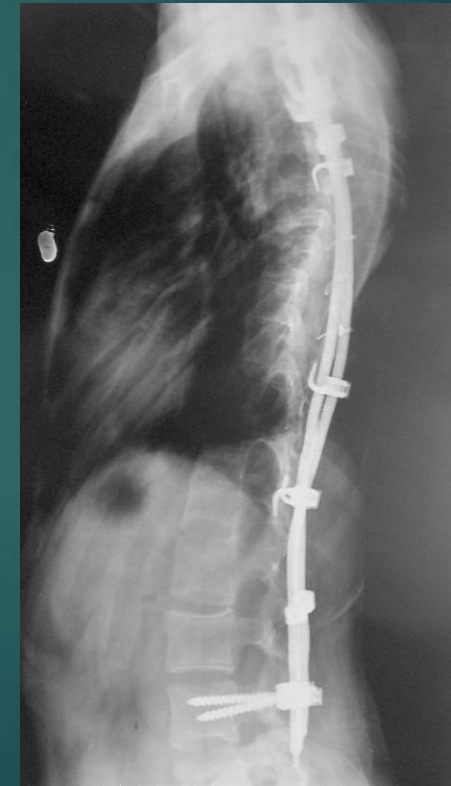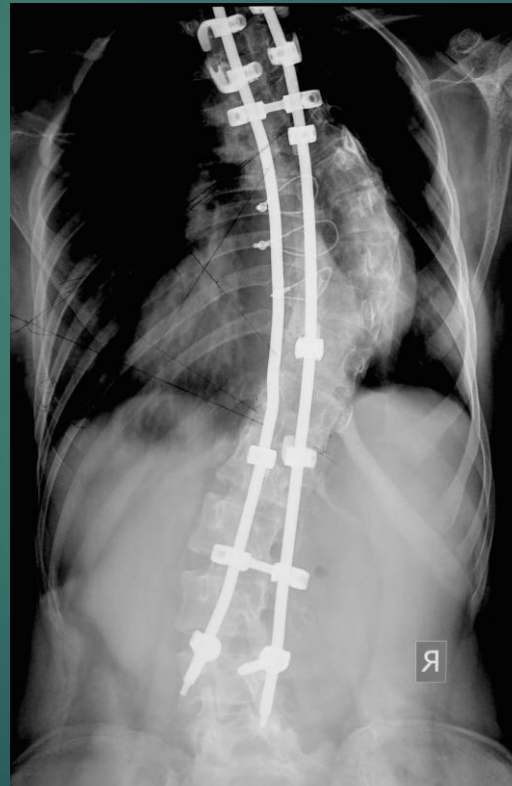Spinal cord monitoring

Post-op

Anterior thoracoscopic
release



Post op Xray



Post op clinical snaps

After 1 month



After 24 months

