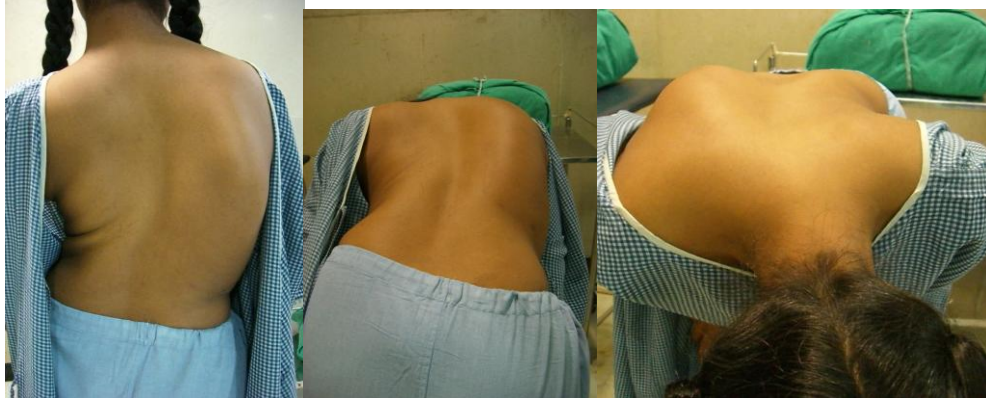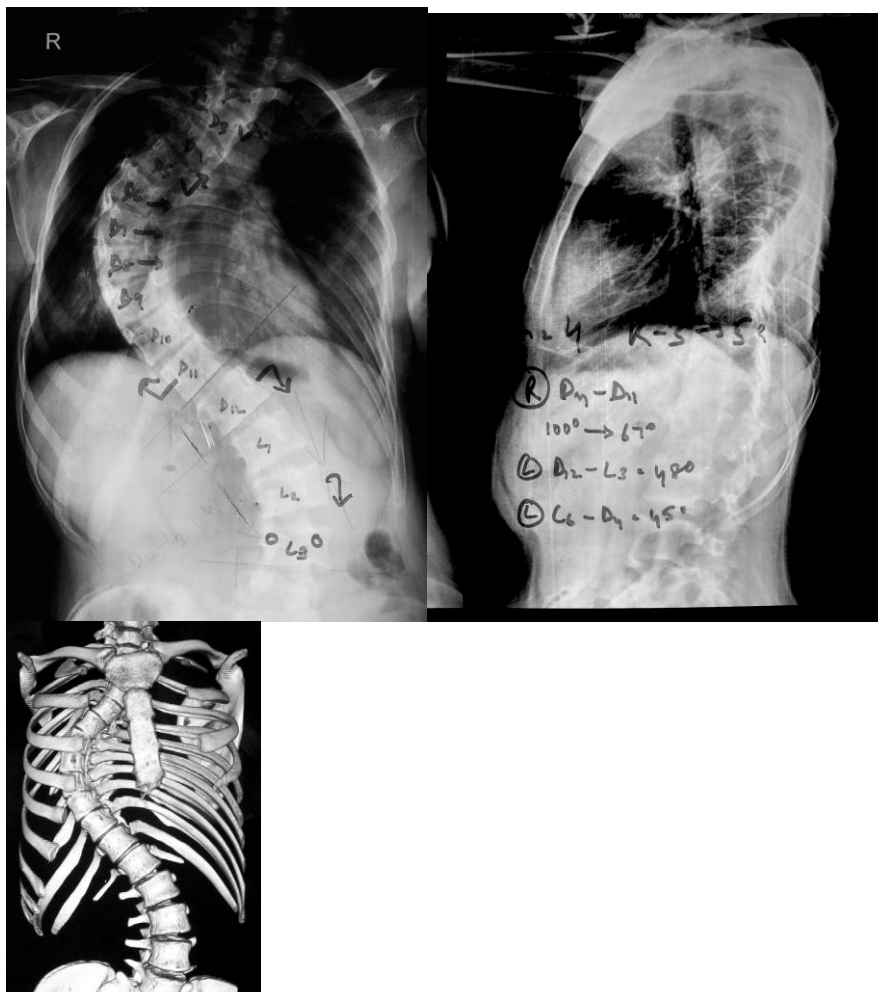


A. Scoliosis

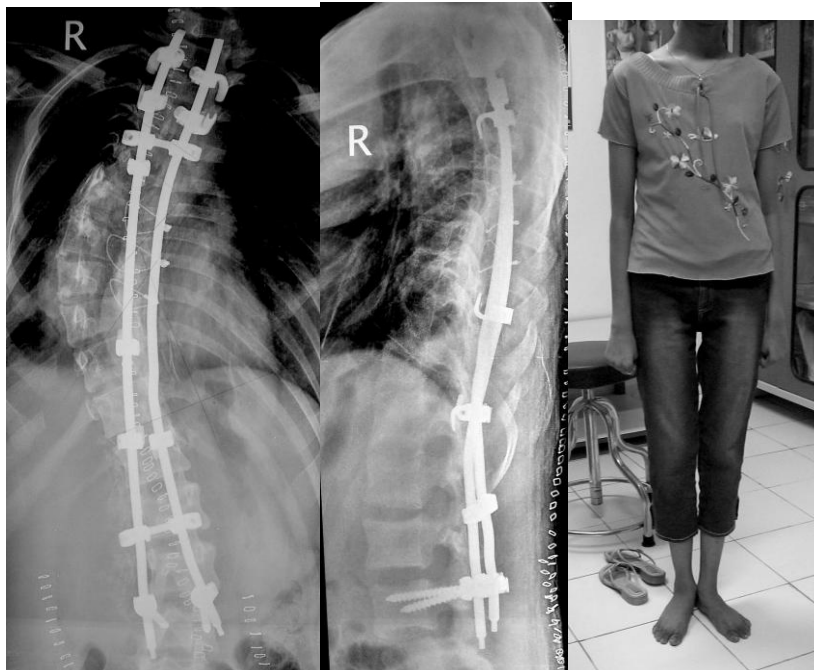
16 year old girl presenting with head & trunk asymmetry & back deformity since 6 years.
No history of any proper treatment given. No h/o backache.



Standing erect Dorso-lumbo-sacral spine PA & Lateral views with planning. CT also done.



Post operative X-rays standing erect PA & Lateral, after 10 days of surgery. Clinical picture after a month. Segmental fixation with hooks, pedicular screws & rods.



Post op Clinical picture after 2 years of surgery. The curve was arrested, good head-trunk balance achieved along with a reasonable correction which was maintained.

